

SCUBA DIVERS' PULMONARY EDEMA: 14 years experience review

Alba Urries, Servei d'Urgències, Hospital de Palamós (Spain) Jose M. Inoriza, Unitat de Medicina Hiperbàrica, Hospital de Palamós (Spain)

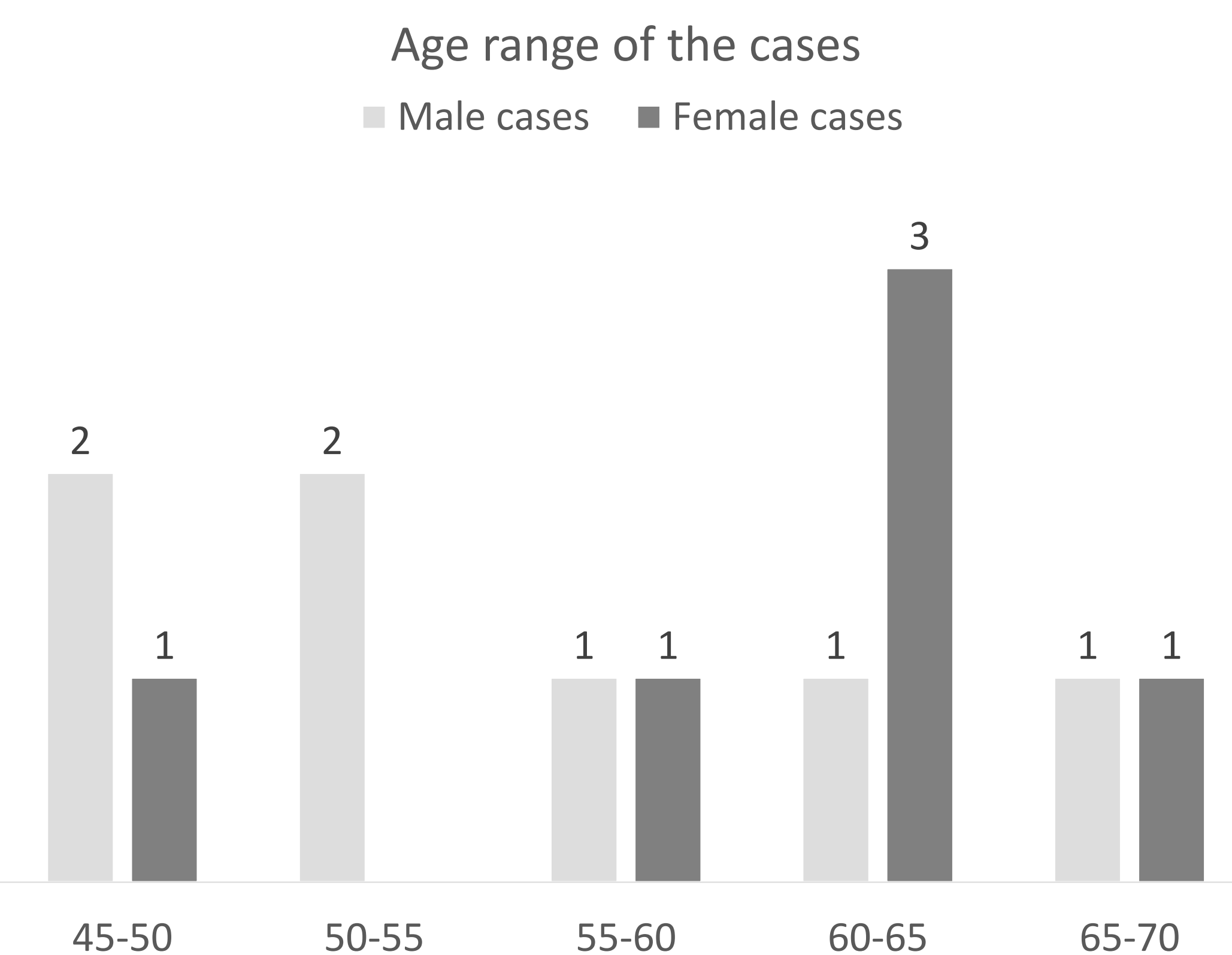
Introduction

The aim is to review the experience of our Unit in the management of Scuba Divers Pulmonary Edema (SDPE)

Materials and methods

SDPE cases diagnosed between 2007 and 2023 are reviewed.

We analyzed data related to people (age, gender, pathological antecedents); the characteristics of the dives; the treatment and the results obtained.



Results

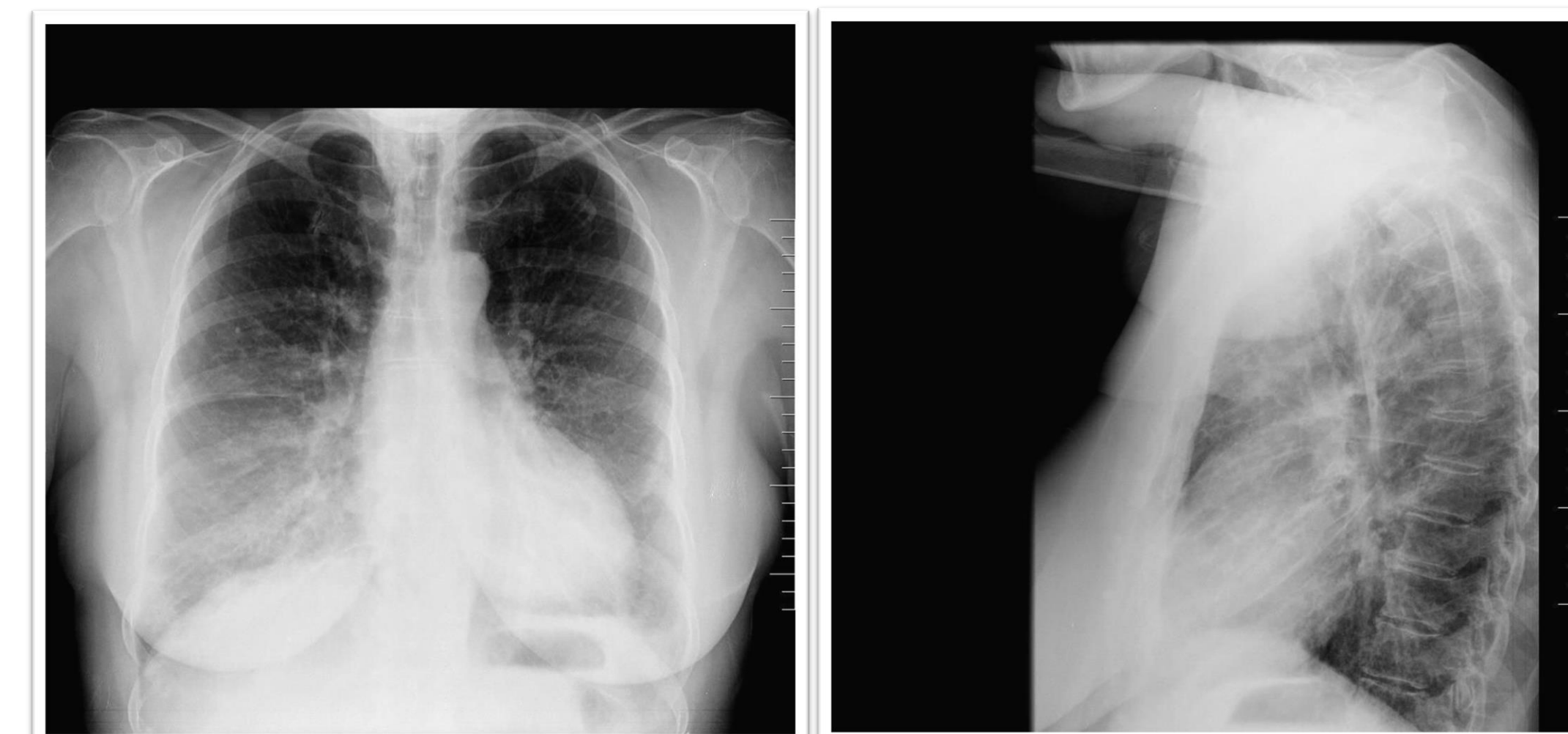
In the period studied, 13 cases were diagnosed (7 men, 6 women), between 46 and 69 years old.

The dives ranged between 3 and 52 meters of maximum depth, with duration of less than 30 minutes, except one of them (42 minutes).

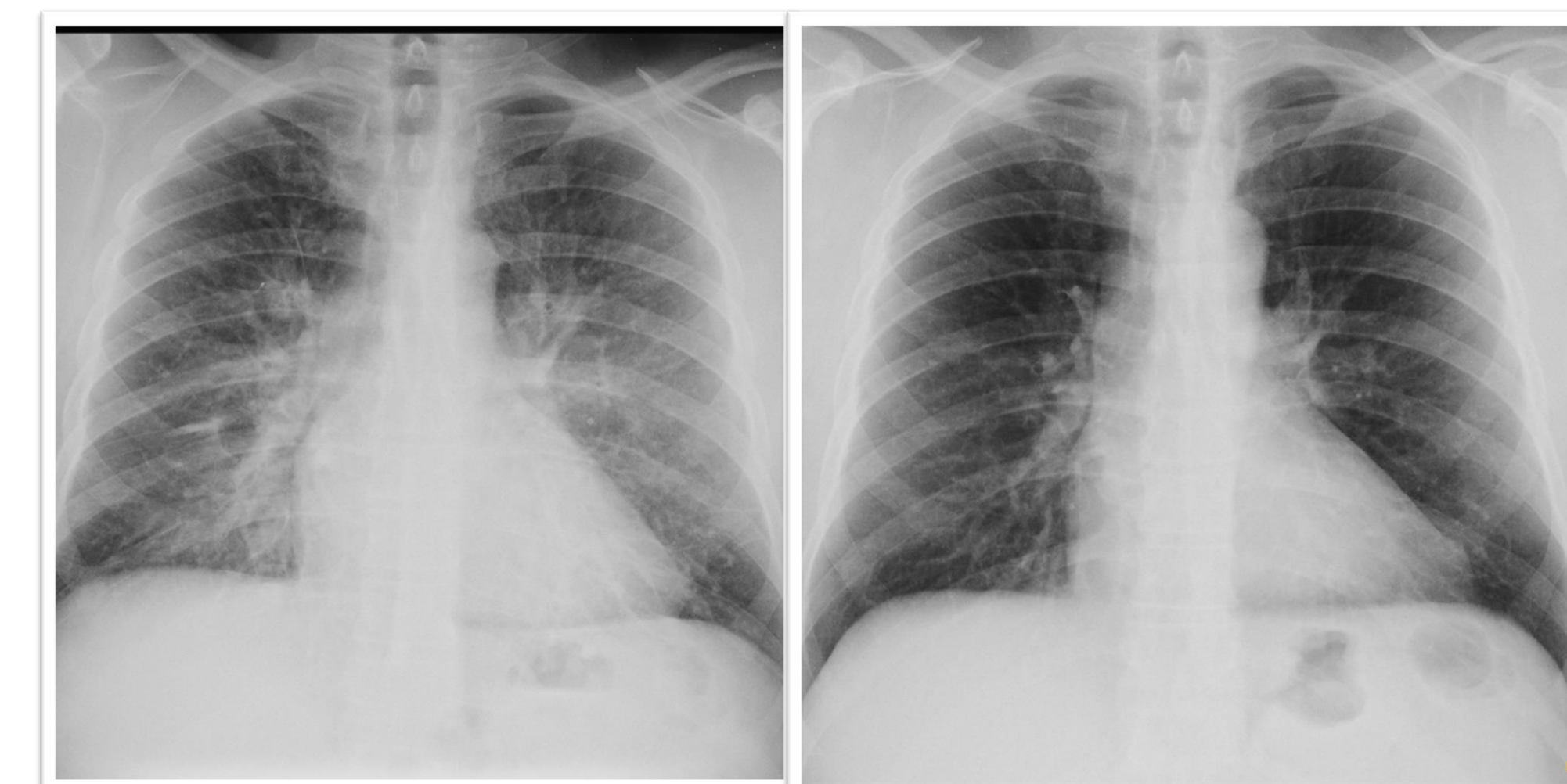
The typical symptomatology was the sudden onset of dyspnea, before the end of the dive (between 3 and 10 meters deep).

In the physical examination, in all cases, basal crackles were present. Only 3 out of 13 presented pulse oximetry lower than 90%.

The diagnosis was made by clinical examination and simple thorax radiography.



Thorax X-ray (AP and lateral) showing Pulmonary Edema on a 64 year old patient (SDPE)



Thorax X-ray (both AP) before and after treatment with Normobaric Oxygen and Furosemide in a SDPE case

Normobaric oxygen therapy and Furosemide were administered in every case, allowing the resolution of the symptoms within 24 hours on average.

In 12 out of 13 cases, the divers did not reside in our area of influence, so it was not possible to make a long-term follow up, neither to investigate the underlying cause.

Conclusions

The SDPE has a simple diagnose and an easy treatment if we are experienced about it

Case review facilitates the diagnosis and treatment of SPDE

Its incidence is expected to increase, as well as the average age of divers.

Could it be a trigger for other accidents, or the underlying cause of death in some cases?

Literature cited

Carl Edmonds M. D., UHM 2016, VOL. 43., NO. 2 – EVOLUTION OF SDPE
Ralph Smith, Julian O M Ormerox, Nikant Sabbharwal, Courtney Kipps. Swimming induced pulmonary edema: current perspectives. Open Access Journal of Sports Medicine 2018:9 131-137.

Further information

A. Urries
aurries@ssibe.cat
J. M. Inoriza
jminoriza@ssibe.cat
Unitat de Medicina Hiperbàrica – Hospital de Palamós